

RECEIVED: SEP 12, 2017

ACCEPTED: DEC 12, 2017

PUBLISHED: DEC 15, 2017

### \*CORRESPONDING AUTHOR:

Jan P. Deroose, Department of Gastro-intestinal and oncological surgery, Amphia Hospital, Netherlands, Tel: 31 76 595 50 00; Email: janderoose@gmail.com

### KEYWORDS

Single port laparoscopy; Stomach

### CITATION

Jan P. Deroose<sup>1\*</sup>, George P. van der Schelling<sup>1</sup>, Tom Seerden<sup>2</sup>, and Paul D. Gobardhan<sup>1</sup>. (2017) Transgastric Single Port Laparoscopy: A Simple Approach for Various Indications. SciTz Gastro. 2017 2(1) 1006.

## TRANSGASTRIC SINGLE PORT LAPAROSCOPY: A SIMPLE APPROACH FOR VARIOUS INDICATIONS

Jan P. Deroose<sup>1\*</sup>, George P. van der Schelling<sup>1</sup>, Tom Seerden<sup>2</sup>, and Paul D. Gobardhan<sup>1</sup>

<sup>1</sup>Department of Gastro-intestinal and oncological surgery, Amphia Hospital Breda, The Netherlands

<sup>2</sup>Department of Gastroenterology, Amphia Hospital Breda, The Netherlands

### Abstract

#### Background

Single port laparoscopy (SPL) is an emerging new laparoscopic technique with good results in experienced hands. A modification to SPL is a transgastric SPL (TSPL) offering several new opportunities in gastric surgery. In this report we present our first experiences with TSPL.

#### Methods

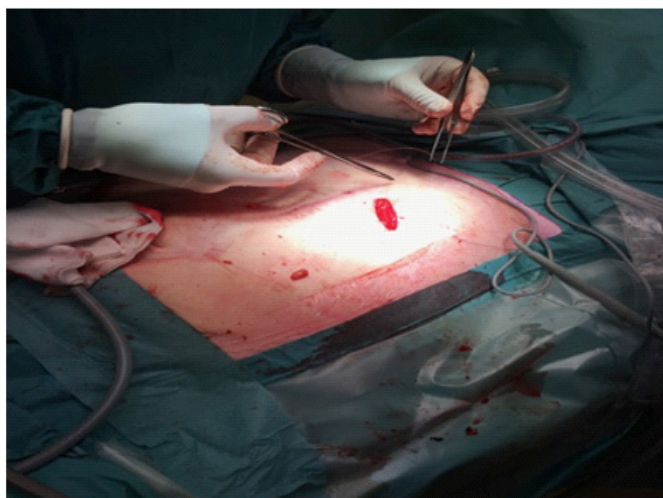
Via a small left sided subcostal laparotomy access is gained to the abdominal cavity. The stomach is fixated to the ventral abdominal wall. After a small gastrotomy a Gelpoint single port system (Applied Medical, Ca, USA) can be placed in the stomach. The stomach is insufflated with CO<sub>2</sub> (pressure 10mm H<sub>2</sub>O).

#### Results

This technique was successfully used in three patients for three different indications. First indication was the removal of an intragastric corpus alienum. In the second patient a gastro intestinal stromal tumor was resected and in the third patient a flexible endoscope for an ERCP was introduced via TSPL in a patient with a gastric bypass.

### Background

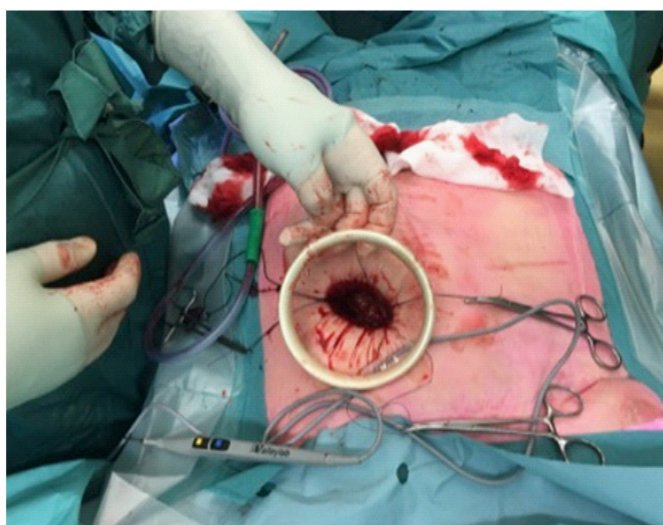
Single port laparoscopy (SPL) is an enhanced laparoscopic technique with comparable results in experienced hands [1]. A modification to SPL is a transgastric SPL (TSPL) offering several new opportunities in gastric surgery. Since there is little experience with this technique, literature on this topic is limited. Possible indications are the removal of corpora aliena such as an eroded gastric band [2], resection of gastric tumor [3], and creation of a reliable access to the distal part of the stomach after a gastric bypass. In this report we present our first experiences with TSPL.



**Figure 1:** It explains Via a small left sided subcostal laparotomy access is gained to the abdominal cavity.

## Patient and Methods

Via a small left sided subcostal laparotomy access is gained to the abdominal cavity (Figure 1). With a few stitches the stomach is fixated to the ventral abdominal wall. After a small gastrotomy a Gelpoint single port system (Applied Medical, Ca, USA) is placed in the stomach (Figure 2) and the stomach is insufflated with CO<sub>2</sub> (pressure 10mm H<sub>2</sub>O) during TSPL. After removal of the Gelpoint the gastrotomy can be closed. Procedure is finished by closure of the abdominal wall and skin.



**Figure 2:** Small gastrotomy a Gelpoint single port system (Applied Medical, Ca, USA) placing in the stomach

## Results

### Case I

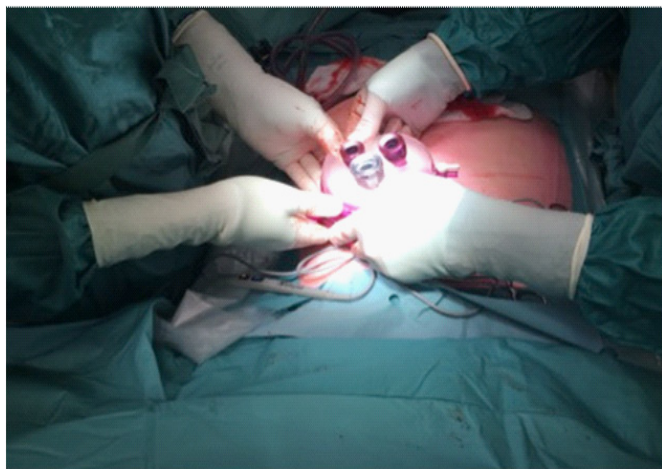
The first TSPL in our center was performed in a 51-year-old woman, with an extensive psychiatric history, who was admitted with abdominal complaints and an unclear anamnesis. Gastroscopy showed multiple pieces of a broken Compact Disc (CD) and bottle nail varnish located in the stomach. Endoscopic removal was not performed because of the risk of esophageal lacerations or perforations. A TSPL was successfully performed and all CD pieces and the bottle of nail varnish were removed. Postoperatively proton pump inhibitors were intravenously administered for three days. Nasogastric tube was removed after four days and patient was discharged to the psychiatric ward in good physical condition.

### Case II

A 53-year-old woman with a medical history of hypertension and hypothyroidism presented with hematemesis at the department of gastro-enterology. Gastroscopy revealed a submucosal tumor at the cardia (20mm x 35mm) with a suspicion of a gastro intestinal stromal tumor (GIST). Computed tomography (CT) showed a lobular mass without in growth in surrounding structures or signs of metastatic disease. Cytological examination of tumor tissue obtained by EUS guided FNA confirmed the diagnosis of GIST. A multi disciplinary board meeting decided to perform a resection by means of a TSPL. Intra-gastric access was achieved as described above. The GIST was radically resected with the use of four staplers (endo-GIA). However, during inspection before closure, a bleeding of the vasa brevia, interpreted as a traction lesion caused by the Alexis, was seen. Once a mini-laparotomy was performed the bleeding could be stopped after local administration of flow seal® (Baxter, United States). Postoperative anemia was treated with a single blood transfusion. Hospital length of stay was prolonged to 15 days due to fever caused by an infected hematoma which could be treated with antibiotics without the need for intervention. Pathological examination of the specimen showed a radical resection of a GIST (maximal diameter 4,7 cm)

### Case III

The last case is a 54-year-old woman with a medical history



**Figure 3:** Case Showing a 54-year-old woman with a medical history of coronary artery bypass graft

of coronary artery bypass graft, a deep venous thrombosis, hypothyroidism, biliary pancreatitis and a gastric bypass (Figure 3). A recurrence of acute mild biliary pancreatitis with dilated intra hepatic bile ducts without clear sign of bile stones in the distal common bile duct led to decision of a laparoscopic cholecystectomy with peroperative endoscopic retrograde cholangio- and pancreaticography (ERCP). After successful cholecystectomy a TSPL was performed to introduce the flexible endoscope in the distal part of the divided stomach. Via ERCP a papilotomy was done and bile sludge in the common bile duct was removed. Postoperative course was uncomplicated and patient was discharged from medical ward after 2 days.

## Discussion

This case series describes the first experiences of transgastric single port laparoscopy (TSPL) for a variety of indications. This technique appeared to be safe and reliable one as there were no major complications and all procedures were successful. There was one conversion to an open approach via a mini-laparotomy needed due to a bleeding. This, probably caused by traction of the Alexis on the spleen. Another explanation for the bleeding might be traction of the stapling device. Mobilizing the gastric fundus before TSLP could perhaps prevent this complication. This event led to the use of a smaller port (Gelpoint Mini, Applied Medical, Ca, USA), which can be used through incisions between 1.5-3 cm.

Surgical access to the stomach with TSPL might be a

more suitable option than a laparotomy in cases of a corpus alienum, giving the easy approach and the optimal view of the stomach due to the insufflations.

ERCP after a gastric bypass is challenging with rather poor success rates (33-72%) [4]. Recent studies reported of laparoscopy-assisted transgastric ERCP as an appropriate option in case of failure of a double balloon ERCP [5-7]. Since TSPL is a relative easy and fast approach it might be a suitable alternative for a laparoscopy. However, more mature series should be awaited to draw any conclusions.

Intragastric operation techniques are uncommon. Recently, Lamm et al. [8], described a technique creating a pneumogastrum via laparoscopy. This study reported of two patients whom had a successful resection of a GIST.

Although indications for TSPL are limited, it is a rather simple and safe technique that can easily solve more complicated problems in carefully selected cases.

## Conclusions

Although indications for TSPL are limited, it is a rather simple and safe technique that can easily solve more complicated problems in carefully selected cases.

## References

1. Champagne BJ, Papaconstantinou HT, Parmar SS, Nagle DA, et al. Single-incision versus standard multiport laparoscopic colectomy: a multicenter, case-controlled comparison. *Ann Surg.* 2012; 255: 66-69.
2. Spitali C, De Vogelaere K, Delvaux G. Removal of Eroded Gastric Bands Using a Transgastric SILS Device. *Case Rep Surg.* 2013; 85: 2747-2783.
3. DE Vogelaere K, van de Winkel N, Simoens C, Delvaux G. Intragastric SILS for GIST, a new challenge in oncologic surgery: first experiences. *Anticancer Res.* 2013; 33: 3359-3363.
4. Lopes TL, Baron TH. Endoscopic retrograde cholangiopancreatography in patients with Roux-en-Y anatomy. *J Hepatobiliary Pancreat Sci.* 2011; 18: 332-338.
5. Mejía R, Achurra P, Gabrielli M, Briceño E, et al. Laparoscopy-Assisted Trans-Gastric Rendez-vous for the Treatment of Common Bile Duct Stones in Patients with Prior Roux-en-Y

- Gastric Bypass. *Obes Surg.* 2016; 26: 2809-2813.
6. Schreiner MA, Chang L, Gluck M, Irani S, et al. Laparoscopy-assisted versus balloon enteroscopy-assisted ERCP in bariatric post-Roux-en-Y gastric bypass patients. *Gastrointest Endosc.* 2016; 75: 748-756.
  7. Bertin PM, Singh K, Arregui ME. Laparoscopic transgastric endoscopic retrograde cholangiopancreatography (ERCP) after gastric bypass: case series and a description of technique. *Surg Endosc.* 2011; 25: 2592-2596.
  8. Lamm SH, Steinemann DC, Linke GR, Eucker D, et al. Total inverse transgastric resection with transoral specimen removal. *Surg Endosc.* 2015; 29: 3363-3366.